

Autologous Adult Stem Cell Transplantation in patients with parkinsonism (N=75)

Vreden, S. | Tamaschke, U.K. | Sipos, L. | Haberland, N. | Happich, D. | Kleinbloesem, C.H.

Introduction

Motor parkinsonism (bradykinesia, hypokinesia, rigidity, tremor and the loss of postural reflexes) is the clinical hallmark of Parkinson's disease, a progressive synucleinopathic diffuse neurodegenerative disorder, caused by a continuous loss of dopaminergic neurons in the midbrain^{1,2}.

Therapeutic strategies in motor parkinsonism comprise only symptomatic treatments, compensating for the striatal dopaminergic deficiency with levodopa/carbidopa and/or dopaminergic agonists³. As of now, neuroprotective/restorative and/or disease-modifying approaches are not available. Recently, the application of Autologous, bone-marrow-derived adult Stem Cells is suggested to offer such intervention in the treatment of Parkinson's disease⁴.

Methods

A total number of 75 patients with Parkinson's disease were treated with adult Autologous Stem Cells derived from the bone marrow and returned the post treatment questionnaires. After collecting and preparing these cells – conform to GMP standards – the cell product was injected intrathecally by lumbar puncture. The patients were then invited to participate in the evaluation of clinical effects of this intervention by completing a post treatment survey 10 days after the treatment and a follow up survey 3-6 months after treatment.

Results

75 Patients, nearly 50% of the total cohort, did complete the clinical evaluation forms. Of these patients, 36 reported clinical improvements. The other patients did not notice any clinical change or did mention natural disease progression. (Figure 1)

According to 21 of those patients, their physicians did confirm their improvements (see Figure 2); five patients were able to decrease and four patients could even fully discontinue their Parkinson's disease related medication.

Most patients reported a decrease of motor parkinsonism (N=29), including rigidity and tremor, resulting in improved speech (N=24), dexterity (N=23), swallowing (N=20), handwriting (N=20), and stability (N=19). Thirty patients also noticed increased motivation and/or initiative. (Figure 3 and Figure 4)

Adverse events, other than those normally to be expected in lumbar puncture, were not reported.

Conclusions

Nearly 50% of the patients with parkinsonism treated with Autologous adult Stem Cells reported clinical effects of this safe intervention, resulting in better functioning and an increased quality of life. On the other hand, 30% of the patients with Parkinsonism reported a stable situation concerning their health condition, which also suggests a positive effect. The reported improvements suggest clinical efficacy after adult Autologous Stem Cell treatment in patients with parkinsonism.

References

1. Meyer AK et al. Restorative approaches in Parkinson's Disease J Neurol Sci. (2010) 93-103
2. Halliday GM and McCann H The progression of pathology in Parkinson's disease Ann N Y Acad Sci (2010) 188-95
3. Wijeyekoon R and Barker RA Cell replacement therapy for Parkinson's disease Biochim Biophys Acta (2009) 688-702
4. Venkataramana NK Open-labeled study of unilateral autologous bone-marrow-derived mesenchymal stem cell transplantation in Parkinson's disease Transl Res (2010) 55-6

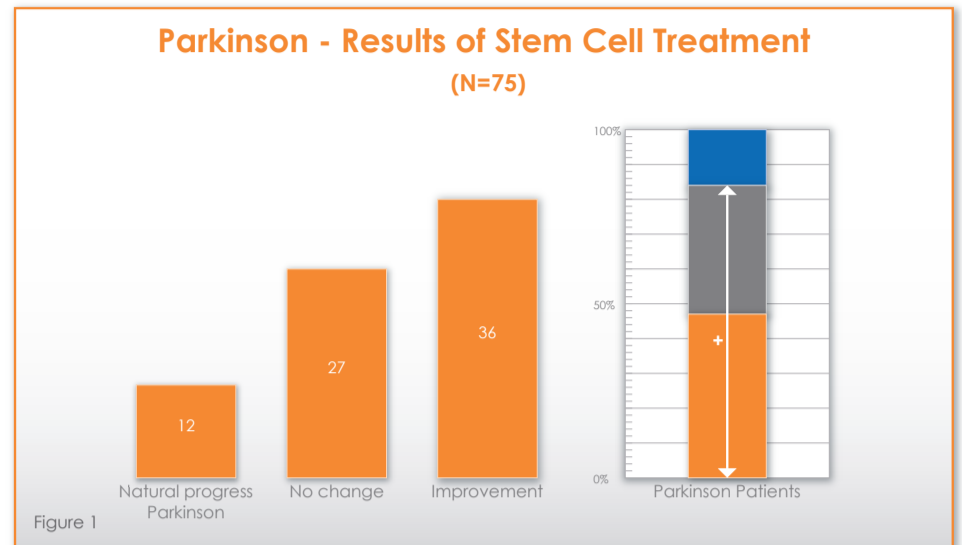


Figure 1

Confirmation Improvement Parkinson (n=33/N=75)

Table: Number of patient improvements confirmed by treating physician (n=33/N=75)

	No doctor visited	Improvement confirmed by own physician	Improvement not confirmed by own physician
My Parkinson improved significantly stated by patient	2 (6.1%)	4 (12.1%)	0
My Parkinson improved stated by patient	9 (27.3%)	17 (51.5%)	1 (3.0%)
Total group Parkinson patients	11 (33.4%)	21 (63.6%)	1 (3.0%)

Figure 2

Kind of reported improvements Parkinson Part 1: Concerning Daily Living aspects

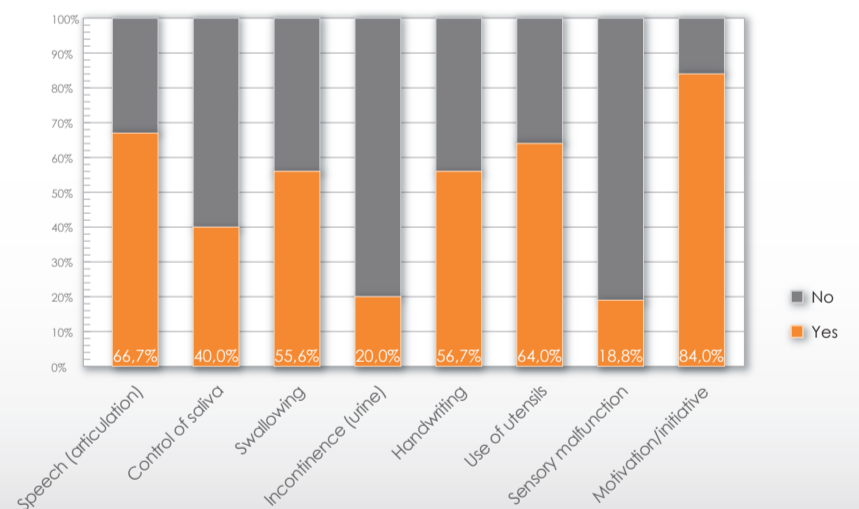


Figure 3

Kind of reported improvements Parkinson Part 2: Concerning Motor Functions

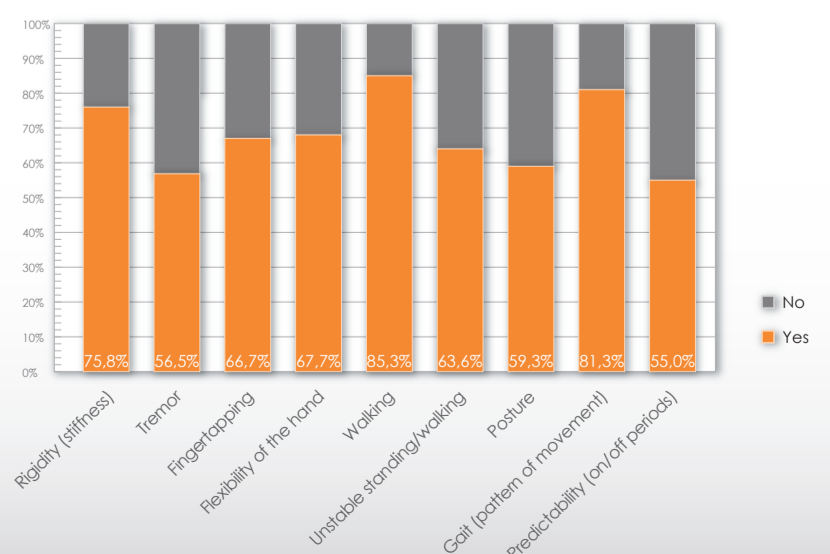


Figure 4